

species identification and ensure that staff use proper biosafety measures.

A total of 19 cases of melioidosis acquired in the Caribbean have been reported (Table). Nine of these were travel related, suggesting that melioidosis may be emerging as a travel health issue. Travelers with known risk factors for melioidosis, such as diabetes mellitus and chronic lung disease, should be informed of their increased infection risk. Physicians should include *B. pseudomallei* in the differential diagnosis of travelers with pneumonia or sepsis who are returning from the Caribbean, particularly when they have a history of travel during the rainy season, soil-contaminated wounds, or known risk factors for melioidosis.

Acknowledgment

We thank the National Microbiology Laboratory for confirming the identification of the *B. pseudomallei* isolate and performing molecular testing and antimicrobial susceptibility testing.

References

1. Clinical and Laboratory Standards Institute. Methods for antimicrobial dilution and disk susceptibility testing of infrequently isolated or fastidious bacteria. CLSI document M45-A2. 2nd ed. Wayne (PA): The Institute; 2010.
2. Godoy D, Randle G, Simpson AJ, Aanensen DM, Pitt TL, Kinoshita R, et al. Multilocus sequence typing and evolutionary relationships among the causative agents of melioidosis and glanders, *Burkholderia pseudomallei* and *Burkholderia mallei*. *J Clin Microbiol*. 2003;41:2068–79. <http://dx.doi.org/10.1128/JCM.41.5.2068-2079.2003>
3. McDowell F, Varney PL. Melioidosis, report of first case from the Western Hemisphere. *J Am Med Assoc*. 1947;134:361. <http://dx.doi.org/10.1001/jama.1947.72880210001008>
4. Doker TJ, Sharp TM, Rivera-Garcia B, Perez-Padilla J, Benoit TJ, Ellis EM, et al. Contact investigation of melioidosis cases reveals regional endemicity in Puerto Rico. *Clin Infect Dis*. 2015;60:243–50. <http://dx.doi.org/10.1093/cid/ciu764>
5. Inglis TJ, Rolim DB, Sousa Ade Q. Melioidosis in the Americas. *Am J Trop Med Hyg*. 2006;75:947–54.
6. Corral DM, Coates AL, Yau YC, Tellier R, Glass M, Jones SM, et al. *Burkholderia pseudomallei* infection in a cystic fibrosis patient from the Caribbean: a case report. *Can Respir J*. 2008;15:237–9.
7. O'Sullivan BP, Torres B, Conidi G, Smole S, Gauthier C, Stauffer KE, et al. *Burkholderia pseudomallei* infection in a child with cystic fibrosis: acquisition in the Western Hemisphere. *Chest*. 2011;140:239–42. <http://dx.doi.org/10.1378/chest.10-3336>
8. Meckenstock R, Therby A, Marque-Juillet S, Monnier S, Khau D, Pangon B, et al. Cutaneous melioidosis in adolescent returning from Guadeloupe. *Emerg Infect Dis*. 2012;18:359–60. <http://dx.doi.org/10.3201/eid1802111603>
9. Gétaz L, Abbas M, Loutan L, Schrenzel J, Iten A, Simon F, et al. Fatal acute melioidosis in a tourist returning from Martinique Island, November 2010. *Euro Surveill*. 2011;16:19758.
10. Mickail N, Klein NC, Cunha BA, Schoch PA. Melioidosis breast abscesses. *J Infect*. 2012;64:434–5. <http://dx.doi.org/10.1016/j.jinf.2011.12.016>

Address for correspondence: Melanie Murray, BC Women's Hospital & Health Centre, E600B, 4500 Oak St, Vancouver, BC V6H 3N1, Canada; email: Melanie.Murray@cw.bc.ca

Probable Toxic Cause for Suspected Lychee-Linked Viral Encephalitis

Peter S. Spencer, Valerie S. Palmer, Rajarshi Mazumder

Author affiliations: Oregon Health & Science University, Portland, Oregon, USA (P.S. Spencer, V.S. Palmer); Legacy Health, Portland (R. Mazumder)

DOI: <http://dx.doi.org/10.3201/eid2105.141650>

To the Editor: Paireau et al. (1) reported a spatiotemporal association between unexplained outbreaks of suspected acute encephalitis in children in northern Vietnam and the harvesting of lychee (litchi) fruit. The clinical, biologic, and immunologic characteristics of the patients suggested a viral etiology (1). However, the lychee-associated acute brain disorder, which has also been reported in Bangladesh and India (Bihar and West Bengal), could also result from ingestion of phytotoxins present in lychee fruit, specifically a-(methylenecyclopropyl)glycine (2), the lower homologue of the neurotoxic L-amino acid hypoglycine (3,4).

As previously described (5), ingestion of the hypoglycine-rich fruit of ackee, a relative of lychee, can induce a dose-dependent toxic hypoglycemic encephalopathy in poorly nourished children. The syndrome is best known from Jamaica, where ackee is widely eaten, and occurs most frequently in 2- to 10-year-old children, who develop severe hypoglycemia and metabolic acidosis. Clinical manifestations of Jamaican vomiting sickness include headache, thirst, sweating, vomiting, lethargy, seizures, coma, and death over a span of hours to days. Patients may be mildly to moderately febrile, and emesis may not be present in all cases. Heavy ingestion of the immature aril (fruit) of ackee (*Blighia sapida*) or other members of the soapberry family (Sapindaceae), including lychee (*Litchi sinensis*), rambutan (*Nephelium lappaceum*), and longan (*Dimocarpus longan*), by an undernourished child with low glycogen/glucose stores probably has the potential to result in toxic hypoglycemic syndrome.

Assessment of finger-prick blood glucose levels, which may be markedly depressed in children with severe Sapindaceae fruit poisoning, provides a rapid and convenient screening tool to identify suspected cases. Intravenous administration of glucose is the first line of treatment, along with serial monitoring of glucose, serum aminotransferase, and serum creatinine levels. Restoration of body fluid, electrolytes, glucose, and pH balance is the goal of supportive treatment.

Note added in proof. Subsequent to the submission of this letter, a description was published of recent outbreaks

of unexplained acute hypoglycemic encephalopathy in young children in Muzaffarpur, Bihar, coinciding with local lychee harvests (6).

References

1. Paireau J, Tuan NH, Lefrançois R, Buckwalter MR, Nghia ND, Hien NT, et al. Litchi-associated acute encephalitis in children, northern Vietnam, 2004–2009. *Emerg Infect Dis*. 2012;18:1817–24. <http://dx.doi.org/10.3201/eid1811.111761>
2. Gray DO, Fowden L. a-(methylenecyclopropyl)glycine from *Litchi* seeds. *Biochem J*. 1962;82:385–9.
3. Spencer PS. Hypoglycine. In: Spencer PS, Schaumburg HH, editors. *Experimental and clinical neurotoxicology*. 2nd ed. Oxford (NY); 2000. p. 669–72.
4. John TJ, Das M. Acute encephalitis syndrome in children in Muzaffarpur: hypothesis of toxic origin. *Curr Sci*. 2014;106:1184–5.
5. Centers for Disease Control and Prevention. Toxic hypoglycemic syndrome—Jamaica, 1989–1991. *MMWR Morb Mortal Wkly Rep*. 1992;41:53–5.
6. Shrivastava A, Srikanthiah P, Kumar A, Bhushan G, Goel K, Kumar S, et al. Outbreaks of unexplained neurologic illness—Muzaffarpur, India, 2013–2014. *MMWR Morb Mortal Wkly Rep*. 2015;64:49–53.

Address for correspondence: Peter S. Spencer, Oregon Health & Science University, 3181 SW Sam Jackson Park Rd, L356, Portland, OR 97239-3098, USA; email: spencer@ohsu.edu

Pin-Site Myiasis Caused by Screwworm Fly, Colombia

Francisco J. Africano, Álvaro A. Faccini-Martínez, Carlos E. Pérez, Alejandro Espinal, Juan S. Bravo, Carlos Morales

Author affiliations: Universidad Militar Nueva Granada, Bogota, Colombia (F.J. Africano); Servicios y Asesorías en Infectología, Bogota (Á.A. Faccini-Martínez); Hospital Militar Central, Bogota (C.E. Pérez, A. Espinal, J.S. Bravo, C. Morales)

DOI: <http://dx.doi.org/10.3201/eid2105.141680>

To the Editor: Myiasis is the infestation of humans or animals with dipterous insect larvae (1). The term pin-site myiasis was recently adopted for a rare and emerging

parasitic infection after treatment of open fractures with external metal fixators (pins). Myiasis can also occur as a result of invasion of larvae deposited by flies in wounds adjacent to these fixators (1,2). We describe a patient with pin-site myiasis caused by the *Cochliomyia hominivorax* screwworm fly associated with external fixators used for treatment of an open fracture of the femur.

In September 2014, a 26-year-old male soldier from the Department of Meta in central Colombia was admitted to a primary medical unit for treatment of an open fracture of the right femur after a traffic accident. The patient had no relevant medical history. After multiple surgical interventions and external fixation of the fracture, he was discharged. Two weeks later, he returned to the medical unit with edema, redness, and warmth in the area surrounding the metallic fixators. At this time, 50 larvae were observed in the surgical wound (Figure, panel A).

The patient was referred to Hospital Militar Central in Bogota, Colombia, where surgical cleansing of the wound was performed and 30 additional larvae were obtained (Figure, panel B). Extracted larvae were sent to the Parasitology Laboratory of the Universidad Nacional de Colombia in Bogota, Colombia for identification. The larvae were taxonomically classified as those of the *C. hominivorax* screwworm fly.

Treatment with oral ivermectin and intravenous ampicillin/sulbactam was initiated. The next day, surgical cleansing showed signs of osteomyelitis. A culture of bone tissue was positive for multidrug-susceptible *Pseudomonas aeruginosa* and *Stenotrophomonas maltophilia* susceptible to trimethoprim/sulfamethoxazole (TMP/SMX). At this time, antimicrobial drug therapy was changed to intravenous ciprofloxacin (400 mg every 12 h) and oral TMP/SMX (160/800 mg every 12 h). The patient completed 2 weeks of treatment in the hospital and showed no signs or symptoms of infection or infestation by larvae. He was discharged, prescribed oral TMP/SMX, and followed up by the Orthopedics and Infectious Diseases Service of Hospital Militar Central.

Bacterial infection in insertion sites of metallic pins is usually the most frequent complication when external fixators are used in treatment open fractures and represents

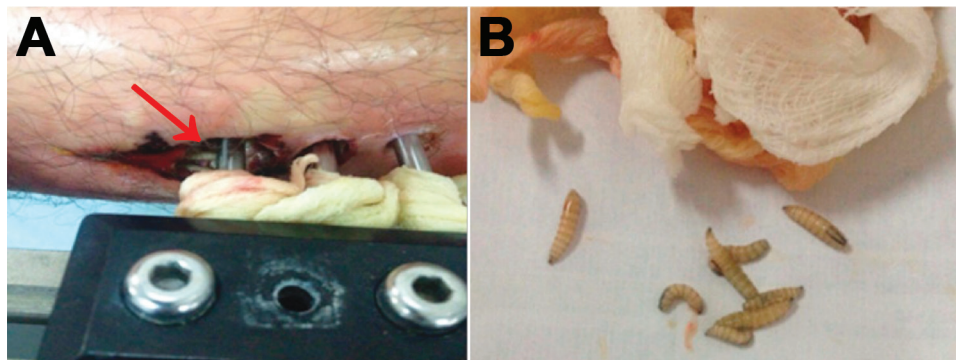


Figure. Pin-site myiasis in a 26-year-old male soldier, Colombia. A) Larvae of *Cochliomyia hominivorax* screwworm fly around an external metallic fixator (arrow). B) Larvae isolated from the insertion wound of the external metallic fixator. A color version of this figure is available online (<http://wwwnc.cdc.gov/EID/article/21/05/14-1680-F1.htm>).